

Feature Article

THE NEXT GENERATION OF MOHS—CAN IMAGING GUIDE SURGERY?

By **Yogesh Patel, MS**
Research Engineer

Memorial Sloan-Kettering
Cancer Center

Mohs micrographic surgery is a multistep procedure combining surgery and histology for the treatment of skin cancer. The classic indication for Mohs surgery is non-melanoma skin cancer in high risk facial areas with functional and cosmetic implications, such as close proximity to the ears, nose or eyes. Mohs surgery has a higher cure rate for primary and recurrent basal cell carcinomas (BCCs) than any other treatment modality, as well as superior tissue conservation.

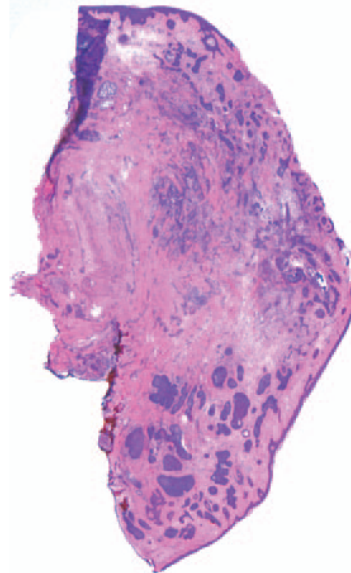
The Mohs surgery procedure begins with excision of the tumor area, followed by immediate frozen section processing for histology. The surgeon examines the tissue sections for tumor in the peripheral and deep margins. If the margin is positive for cancer, additional excisions are undertaken and examined until the last section is negative for cancer.

The drawback of Mohs surgery is that it is time-consuming - each excision stage takes 45-60 minutes since the specimen must be processed by frozen H&E sections and examined by the surgeon. Several excisions are required, totaling 2-4 hours from skin excision to wound closure. Furthermore, during this process, the patient has to wait under local anesthesia with an open wound.

Reflectance confocal microscopy (RCM) may enable rapid detection of BCCs directly in surgical skin excisions, minimizing the need for frozen histology. Thus RCM expedites Mohs surgery and benefits both patient and surgeon.

The RCM has a point source of light

that illuminates a spot in the skin. The backscattered light from the tissue is transmitted through a spatial filter, which allows only light from the plane of focus, and blocks out-of-focus light. The focused light is detected to produce a sharp, real-time image. The acquisition of sequential images over a large area creates a composite mosaic of the tissue comparable to the magnifications used in standard histology. In addition, RCM images show nuclear and cellular morphology in thin optical sections with high resolution and contrast. RCM allows for the ability to precisely control depth of imaging and produce optical sectioning, thus excised specimens need not be cut into thin slices, but are imaged *en-block*.



For RCM to be fully adaptable for Mohs surgery, various biological and technical challenges need to be addressed. First, to facilitate detection of BCC nests within the RCM image, the tissue specimen was soaked with acetic acid, a chemical process known as "acetowhitening." This causes compaction of the chromatin within the nucleus, increasing backscatter, and brightening the nuclei in the RCM images. In addition, RCM is limited to a 0.5mm field-of-view, which is impractical for the need of tumor mapping in Mohs. However, technical advancements in instrumentation and image software allow for creating a seamless composite mosaic from the individual images, giving a field-of-view of up

to 12mm that better correlates to histology (Figure 1).

Currently, RCM has been only applied to the excisions *ex vivo* from Mohs surgery, as the RCM is a relatively large apparatus, limiting its bedside use. However, in the next phase of research, a handheld RCM will be developed to non-invasively map tumor margins *in vivo*, pre-operatively. This may guide the surgeon into more precise initial excision, obviating the need for multiple-step excisions. Furthermore, acetic acid may be applied to the wound edges, and RCM *in vivo* imaging may determine whether there are positive margins for remaining tumor. This may further reduce surgery time and cost.

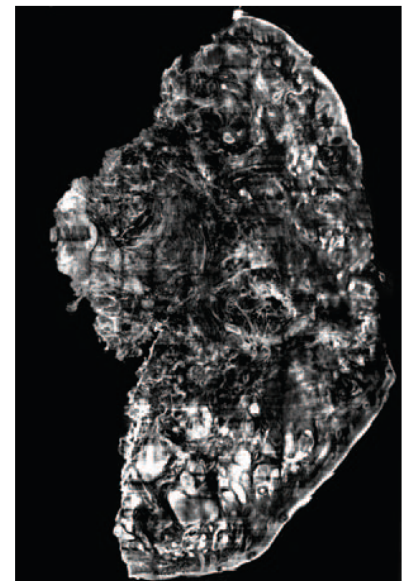


Figure 1.

Left: Frozen H&E histopathology section showing micronodular BCC (arrow).

Right: The correlating RCM mosaic, with acetowhitening technique, showing enhanced BCC-to-dermis contrast. RCM is performed after frozen histology processing and thus the image is approximately 10-15µ deeper into the excised specimen.

Scale bar is 500µ.

Overall, the outlook for the application of reflectance confocal microscopy in Mohs micrographic surgery shows great promise.